



# Flapless Approach to Maxillary Sinus Augmentation Using Minimally Invasive Antral Membrane Balloon Elevation

Ziv Mazor, DMD,\* Efraim Kfir, DMD,† Adi Lorean, DMD,‡ Eitan Mijiritsky, DMD,§ and Robert A. Horowitz, DDS||

Posterior maxillary implant placement is often complicated by the lack of quality and volume of available bone. Types 3 and 4 bone tend to predominate in the posterior maxilla, generally exhibiting the least dense bone of the oral anatomy.<sup>1</sup> The height and width of the residual ridge can significantly be reduced or eliminated by postextraction resorption patterns, use of a removable prosthesis, physical trauma, periodontal disease, and pneumatization of the sinus. In the atrophic posterior maxilla, longer and wider implants are needed to enhance long-term survival. This often requires bone augmentation beneath the sinus to increase the vertical bone height.

Tatum<sup>2</sup> was the first to report the subantral augmentation or “sinus lift” procedure, which has evolved over the past 25 years. A lateral window (modified Caldwell-Luc) approach to the maxillary sinus is used. Because this has shown favorable results, the posterior maxilla is often considered one of the most predictable regions for grafting before or simultaneously with implant placement.<sup>2–7</sup> Basically, a hinged window is created in the lateral wall of the maxilla.<sup>8</sup> When completed,

*In the atrophic posterior maxilla, successful implant placement is often complicated by the lack of quality and volume of available bone. In these cases, sinus floor augmentation is recommended to gain sufficient bone around the implants. Sinus elevation can be performed by either an open lateral window approach or by a closed osteotome approach depending on available bone height. This case series demonstrates the feasibility and safety of minimally invasive antral membrane balloon elevation, followed by bone augmentation and implant fixation in 20 patients with a residual bone height of 2 to 6 mm below the sinus*

*floor. The surgical procedure was performed using a flapless approach. At 18 months follow-up, the implant survival rate was 100%. Absence of patient morbidity and satisfactory bone augmentation with this minimally invasive procedure suggests that minimally invasive antral membrane balloon elevation should be considered as an alternative to some of the currently used methods of maxillary bone augmentation. (Implant Dent 2011;20:434–438)*

**Key Words:** *antral membrane, posterior maxillary implants, bone augmentation, dental implants, maxillary sinus*

the window is gently pressed inward and upward into the sinus cavity, which lifts the Schneiderian membrane and serves as a new sinus floor. The void between the elevated tissues and the original sinus floor is filled with bone graft material. Implants may be simultaneously placed or the graft may be allowed to heal before implant placement.<sup>9–12</sup>

The “osteotome technique,”<sup>13</sup> also called bone-added osteotome sinus floor elevation (BAOSFE), is an alternative approach for sinus elevation where a small amount of bone height is missing. It is not suitable for patients with markedly reduced initial bone height.<sup>14</sup> BAOSFE can be complicated by membrane perforation and tear,<sup>15</sup> which can be reduced with expert technique and specially designed instrumentation.<sup>16</sup> The lateral maxil-

lary window offers an average implant survival rate of 91.8% (range, 61.7%–100%)<sup>6</sup> but involves potential complications (membrane tear, bleeding, infection, and sinus obstruction), swelling and discomfort, and relative contraindications (sinus convolution septum or narrow sinus and previous sinus surgery). Considerable surgical skills, equipment, and time are also required. A modification of the BAOSFE method is the minimally invasive antral membrane balloon elevation (MIAMBE). Antral membrane elevation is performed through the osteotomy site ( $\leq 3.5$  mm) using a specially designed balloon. The use of this technique as an alternative to conventional procedures has been shown.<sup>17–20</sup>

Advantages of using a flapless approach for dental implant placement

\*Private Practice, Ra'anana, Israel.

†Private Practice, Petach Tikva, Israel.

‡Private Practice, Tiberias, Israel.

§Private Practice, Tel Aviv, Israel.

||Assistant Clinical Professor, Departments of Periodontics and Implantology, Oral Surgery, New York College of Dentistry, NY.

Reprint requests and correspondence to: Ziv Mazor, DMD, 142 Ahuza Street, Ra'anana 43300, Israel, Phone: 972-97400336, Fax: 972-97602839, E-mail: drmazor@netvision.net.il

ISSN 1056-6163/11/02006-434

Implant Dentistry

Volume 20 • Number 6

Copyright © 2011 by Lippincott Williams & Wilkins

DOI: 10.1097/ID.0b013e3182391fe3

are well known<sup>21-27</sup>—demonstrating predictability, preservation of crestal bone and mucosal health surrounding the implants. A flapless approach combined with MIAMBE has never been described. In this study, a MIAMBE balloon-harboring device (Miambe LTD, Netanya, Israel) was used. This is a stainless steel tube, 3 mm in diameter, that connects on its proximal end to the dedicated inflation syringe and on its distal portion has an embedded single-use silicone balloon. The balloon is inflated with diluted contrast fluid that pushes up the Schneiderian membrane, creating the desired height for implant placement.

The purpose of this study was to describe a case series using this new treatment modality with its advantages through a flapless approach with 18 months follow-up.

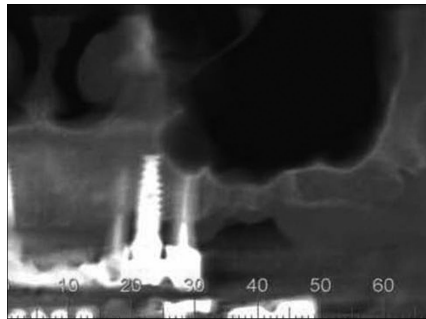
**MATERIALS AND METHODS**

**Patient Selection**

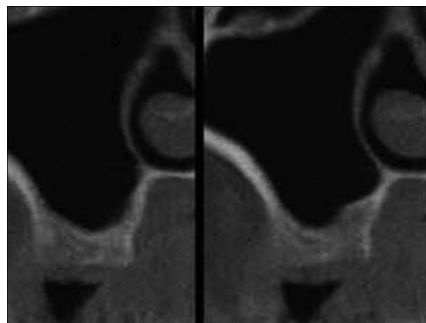
All patients were from the authors' private practices, selected after meticulous evaluation of their medical histories and dental examinations, including panoramic radiographs and dental cone beam CT (CBCT) scans. The mucosa thickness and pathology, bone height and thickness, sinus structure, and major blood vessels were assessed. Patients received an oral explanation regarding the procedure and signed an informed consent. A prerequisite included crestal bone height of 2 to 6 mm between the sinus floor and the alveolar ridge. In 20 patients, ranging in age from 37 to 72 years (mean, 49 years), a total of 24 sinuses were treated and 37 screw-type endosseous implants inserted. All patients were treated under local anesthesia in the dental office.

**Clinical Protocol**

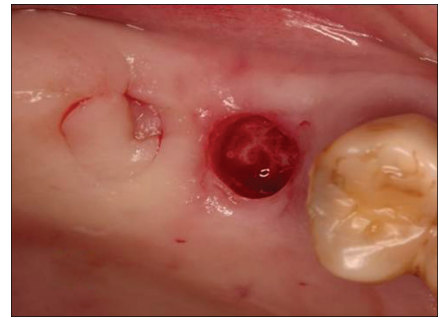
The exact bone height between the alveolar crest and the sinus floor was assessed using preoperative CBCT scans (Figs. 1 and 2). A preprocedural nonsteroidal anti-inflammatory agent, Augmentin (GlaxoSmith Kline, Brentford Middlesex, United Kingdom) (clavulanate potassium), 875 mg, was administered twice, 24 hours before surgery.



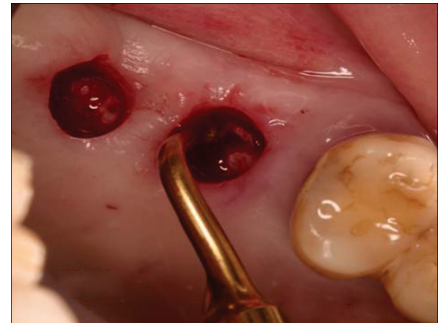
**Fig. 1.** Panoramic projection of the residual ridge underneath the sinus floor.



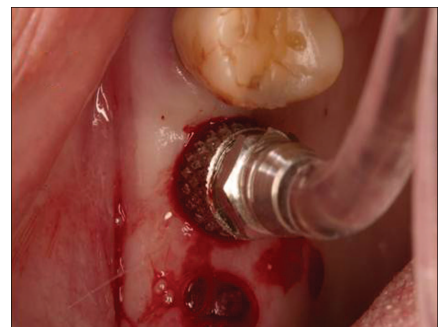**Fig. 2.** CBCT axial cuts of the residual ridge underneath the sinus floor demonstrating 3–4 mm of alveolar bone height.



**Fig. 3.** Underlying bony crest exposed using a 4 mm punch.



**Fig. 4.** Osteotomy preparation using the Piezosurgery device.



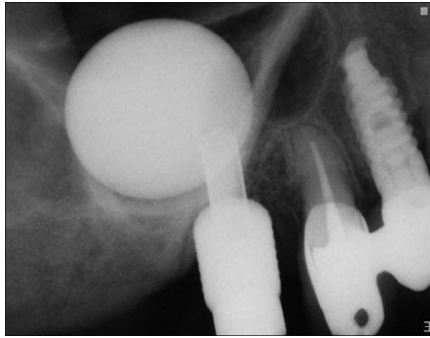
**Fig. 5.** The metal sleeve of the balloon-harboring device inserted into the mesial osteotomy, 1 mm beyond the sinus floor.

Local anesthesia (infiltration of posterior and middle superior alveolar nerve and greater palatine nerve) was administered using 2% lidocaine (Novocol Pharmaceutical Inc., Cambridge, Ontario, Canada). To obtain platelet-rich fibrin (PRF), 40 mL of blood was drawn by venous puncture and processed. Under local anesthesia, a 4-mm diameter punch was used to remove the epithelium with connective tissue and to expose the underlying bone crest at the precise future implant location (Fig. 3).

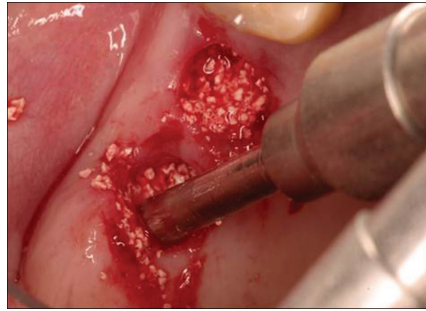
An ultrasonic Piezoelectric (Mectron S.P.A, Genova, Italy) round diameter diamond tip drill was used in the center of the exposed alveolar crest up to 1 to 2 mm below the sinus floor. Depth was predetermined according to measurements obtained from the CT scan and periapical radiographs. The ultrasonic diamond insert was used to deepen the osteotomy until the sinus membrane was reached (Fig. 4). Bone graft material and PRF were inserted into the osteotomy, subsequently enlarging the osteotomy from 2 to 2.9 mm with the

MIAMBE osteotome. After removing the osteotome, the membrane integrity was assessed by Valsalva maneuver.

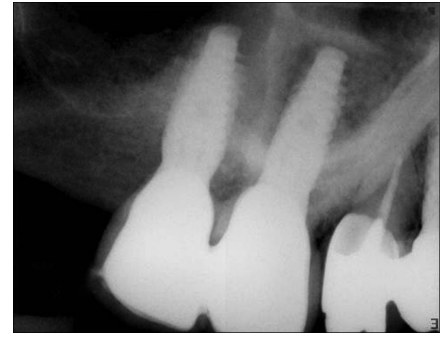
The metal sleeve of the balloon-harboring device (Miambe LTD), specifically designed for sinus augmentation procedures, was inserted into the osteotomy 1 mm beyond the sinus floor (controlled by Teflon stopper) (Figs. 5–8). The balloon was slowly inflated with the barometric inflator up to 2 atm. Once the balloon emerged from the metal sleeve under



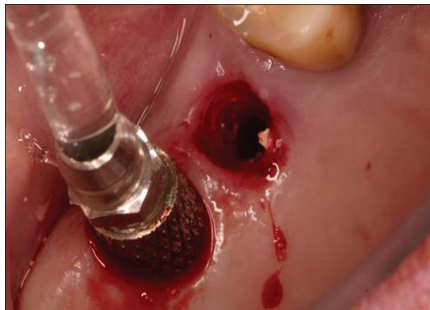
**Fig. 6.** Periapical radiograph demonstrating balloon inflation in mesial site.



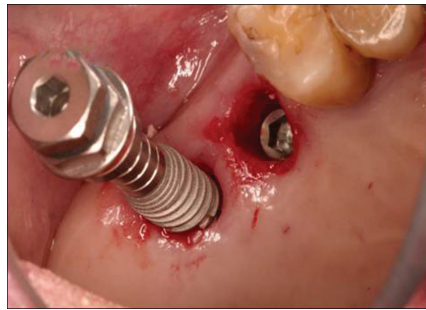
**Fig. 9.** A mixture of xenograft grafting material + PRF is injected to the osteotomy sites after balloon removal.



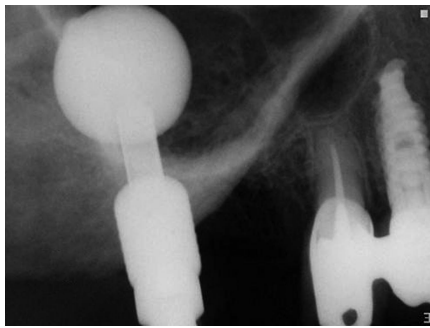
**Fig. 12.** Periapical radiograph 6 months postsurgery.



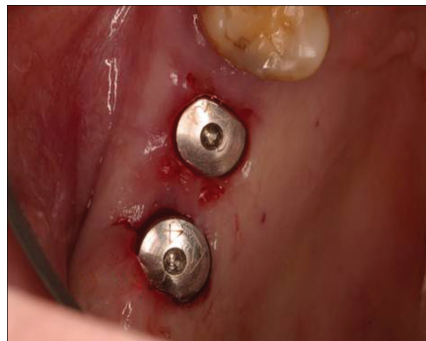**Fig. 7.** The metal sleeve of the balloon-harboring device inserted into the distal osteotomy, 1 mm beyond the sinus floor.



**Fig. 10.** Self-threading implants, 5 mm in diameter and 13 mm long, inserted into the osteotomy sites.



**Fig. 8.** Periapical radiograph showing balloon inflation in the distal site.



**Fig. 11.** Healing abutments screwed into place.

the sinus membrane, the pressure dropped to 0.5 atm. Subsequently, the balloon was inflated with a progressively higher volume of contrast fluid. The same procedure was applied to the second osteotomy site.

Periapical radiographs were taken to evaluate balloon inflation and membrane elevation. After the desired elevation (11 mm) was obtained, the balloon remained inflated in the sinus for 5 minutes to reduce the sinus membrane elasticity. The balloon was

then deflated and removed. Membrane integrity was assessed by Valsalva maneuver and direct visualization assisted by applying a small suction tip.

A bone graft injector was filled with a mixture of bone substitute (Cerabone-Botiss, Berlin, Germany) + PRF and injected through the osteotomy into the sinus under the antral membrane (Fig. 9). Screw-type implants (Adin Touareg-Alon Tavor, Afula, Israel), 13 mm in length and 5 mm in diameter, were inserted (Fig.

10). The healing abutment was connected to the inserted implants and a periapical radiograph verified implant and graft positions (Fig. 11).

Patients were discharged with ibuprofen, 600 mg (single dose) for pain relief and Augmentin, 875 mg twice daily for 7 days. At 6 months postsurgery, patients were evaluated radiographically (panoramic and periapical) before implant exposure. Clinical criteria at the time of implant exposure included stability in all directions, crestal bone resorption, and any reported pain or discomfort. Prosthetic rehabilitation was initiated 3 weeks after implant exposure. Patients were monitored and followed-up for 18 months (Fig. 12).

## RESULTS

All patients received the MIAMBE treatment with immediate implant placement. Healing was uneventful, with no symptoms of pain or edema, postsurgery. One patient, who was allergic to the antibiotic Augmentin (GlaxoSmith Kline, Brentford Middlesex, United Kingdom), was prescribed Clindamycin (Pfizer Pharmaceuticals, Poce Sur Cisse, France).

At 1 week postsurgery, patients were recalled and consequently followed up for 6 months. At 6 months, all implants were successfully integrated. Implants were restored with porcelain fused to metal crowns and followed-up for 18 months. The crestal bone height was maintained and verified by subsequent radiographs. No adverse effects were noted.

## DISCUSSION

This case series supports the proposition that MIAMBE is a minimally invasive, single-sitting procedure of maxillary bone augmentation, and implant placement can be performed where previous conventional lateral window sinus augmentation had been recommended.<sup>17-20</sup>

The “osteotome technique” (BAOSFE) is minimally invasive. However, if the initial height is  $\leq 4$  mm, this method is clearly inferior to the lateral window approach.<sup>28</sup> The BAOSFE yields modest antral membrane elevation and bone augmentation, requires considerable skills, and may frequently result in membrane tear, even when selectively applied<sup>29</sup> and endoscopically controlled. The use of the specific dedicated Miambe balloon enables the operator to predictably elevate the Schneiderian membrane and place implants that are 13-mm long. The successful use of the flapless approach actually requires advanced clinical experience and surgical judgment. The flapless approach together with the MIAMBE used in this study has several advantages over the lateral window approach and the BAOSFE techniques. These include reduced patient trauma, improved patient comfort and recuperation, decreased surgical time, faster soft tissue healing, and normal oral hygiene procedures immediately postsurgery.<sup>23-25</sup> The use of preoperative CBCT measurements and direct visualization of the sinus membrane through the specifically designed suction tip, as well as illumination, can overcome the disability to directly visualize the sinus compartment as seen in the open lateral window approach.

## CONCLUSION

When the advantages of flapless surgery are combined with MIAMBE, the surgeon is able to perform a procedure with minimal postoperative symptoms as well as reduced chair time.

## DISCLOSURE

Dr. Ziv Mazor claims to be a consultant for Adin Implants, Miambe.

Dr. Efraim Kfir claims to be a Board Member and a consultant for Miambe LTD. Dr. Adi Lorean claims to have had, in the past, “administrative support.” The other authors claim to have no financial interest, either directly or indirectly, in any of the products or companies mentioned in this article.

## REFERENCES

1. Truhlar RS, Orenstein IH, Morris HF, et al. Distribution of bone quality in patients receiving endosseous dental implants. *J Oral Maxillofac Surg.* 1997;55(suppl 5):38-45.
2. Tatum H Jr. Maxillary and sinus implant reconstructions. *Dent Clin North Am.* 1986;30:207-229.
3. Boyne PJ, James RA. Grafting of the maxillary sinus floor with autogenous marrow and bone. *J Oral Surg.* 1980;38:613-616.
4. Misch CE. Maxillary sinus augmentation for endosteal implants: Organized alternative treatment plans. *Int J Oral Implantol.* 1987;4:49-58.
5. Block MS, Kent JN, Kallukaran FU, et al. Bone maintenance 5 to 10 years after sinus grafting. *J Oral Maxillofac Surg.* 1998;56:706-714.
6. Wallace SS, Froum SJ. Effect of maxillary sinus augmentation on the survival of endosseous dental implants. A systematic review. *Ann Periodontol.* 2003;8:328-343.
7. Peleg M, Garg AK, Mazor Z. Predictability of simultaneous implant placement in the severely atrophic posterior maxilla: A 9-year longitudinal experience study of 2132 implants placed into 731 human sinus grafts. *Int J Oral Maxillofac Implants.* 2006;21:94-102.
8. Friberg B, Nilson H, Olsson M, et al. Mkll: The self-tapping Brånemark implant: 5-year results of a prospective 3-center study. *Clin Oral Implant Res.* 1997;8:279-285.
9. Froum SJ, Tarnow DP, Wallace SS, et al. Sinus floor elevation using anorganic bovine bone matrix (OstoGraf/N) with and without autogenous bone: A clinical, histologic, radiographic, and histomorphometric analysis—Part 2 of an ongoing study. *Int J Periodontics Restorative Dent.* 1998;18:529-543.
10. Peleg M, Chaushu G, Mazor Z, et al. Radiological findings of the post-sinus lift maxillary sinus: A computerized tomography follow-up. *J Periodontol.* 1999;70:1564-1573.
11. Smiler DG. The sinus lift graft: Basic technique and variations. *Pract Periodontics Aesthet Dent.* 1997;9:885-893.
12. Peleg M, Mazor Z, Chaushu G, et al. Sinus floor augmentation with simultaneous implant placement in the severely atrophic maxilla. *J Periodontol.* 1998;69:1397-1403.
13. Summers RB. Sinus floor elevation with osteotomes. *J Esthet Dent.* 1998;10:164-171.
14. Nkenke E, Schlegel A, Schultze-Mosgau S, et al. The endoscopically controlled osteotome sinus floor elevation: A preliminary prospective study. *Int J Oral Maxillofac Implants.* 2002;17:557-566.
15. Berengo M, Sivoletta S, Majzoub Z, et al. Endoscopic evaluation of the bone-added osteotome sinus floor elevation procedure. *Int J Oral Maxillofac Surg.* 2004;33:189-194.
16. Toffler M. Staged sinus augmentation using a crestal core elevation procedure and modified osteotomes to minimize membrane perforation. *Pract Proced Aesthet Dent.* 2002;14:767-774.
17. Kfir E, Kfir V, Mijiritsky E, et al. Minimally invasive antral membrane balloon elevation followed by maxillary bone augmentation and implant fixation. *J Oral Implantol.* 2006;32:26-33.
18. Kfir E, Kfir V, Eliav E, et al. Minimally invasive antral membrane balloon elevation: Report of 36 procedures. *J Periodontol.* 2007;78:2032-2035.
19. Kfir E, Goldstein M, Rafaelov R, et al. Minimally invasive antral membrane balloon elevation in the presence of antral septa: A report of 26 procedures. *J Oral Implantol.* 2009;35:257-267.
20. Kfir E, Goldstein M, Yerushalmi I, et al. Minimally invasive antral membrane balloon elevation—Results of a multicenter registry. *Clin Implant Dent Relat Res.* 2009;11(suppl 1):e83-e91.
21. Campelo LD, Camara JR. Flapless implant surgery: A 10-year clinical retrospective analysis. *Int J Oral Maxillofac Implants.* 2002;17:271-276.
22. Becker W, Goldstein M, Becker B, et al. Minimally invasive flapless implant surgery: A prospective multicenter study. *Clin Implant Dent Relat Res.* 2005;7:21-27.
23. Rousseau P. Flapless and traditional dental implant surgery: An open, retrospective comparative study. *J Oral Maxillofac Surg.* 2010;68:2299-2306.
24. Noelken R, Kunkel M, Wagner W. Immediate implant placement and provisionalization after long-axis root fracture and complete loss of the facial bony lamella. *Int J Periodontics Restorative Dent.* 2011;31:175-183.
25. Ravindran DM, Sudhakar U, Ramakrishnan T, et al. The efficacy of flapless implant surgery on soft-tissue profile comparing immediate loading implants to delayed loading implants: A comparative clinical study. *J Indian Soc Periodontol.* 2010;14:245-251.

26. Bayounis AM, Alzoman HA, Jansen JA, et al. Healing of peri-implant tissues after flapless and flapped implant installation. *J Clin Periodontol*. 2011;38:754-761.

27. Barter S. Computer-aided implant placement in the reconstruction of a se-

verely resorbed maxilla—A 5-year clinical study. *Int J Periodontics Restorative Dent*. 2010;30:627-637.

28. Rosen PS, Summers R, Mella-do JR, et al. The bone-added osteo-tome sinus floor elevation technique: Multicenter retrospective report of

consecutively treated patients. *Int J Oral Maxillofac Implants*. 1999;14:853-858.

29. Fugazzotto PA. Augmentation of the posterior maxilla: A proposed hierarchy of treatment selection. *J Periodontol*. 2003;74:1682-1691.