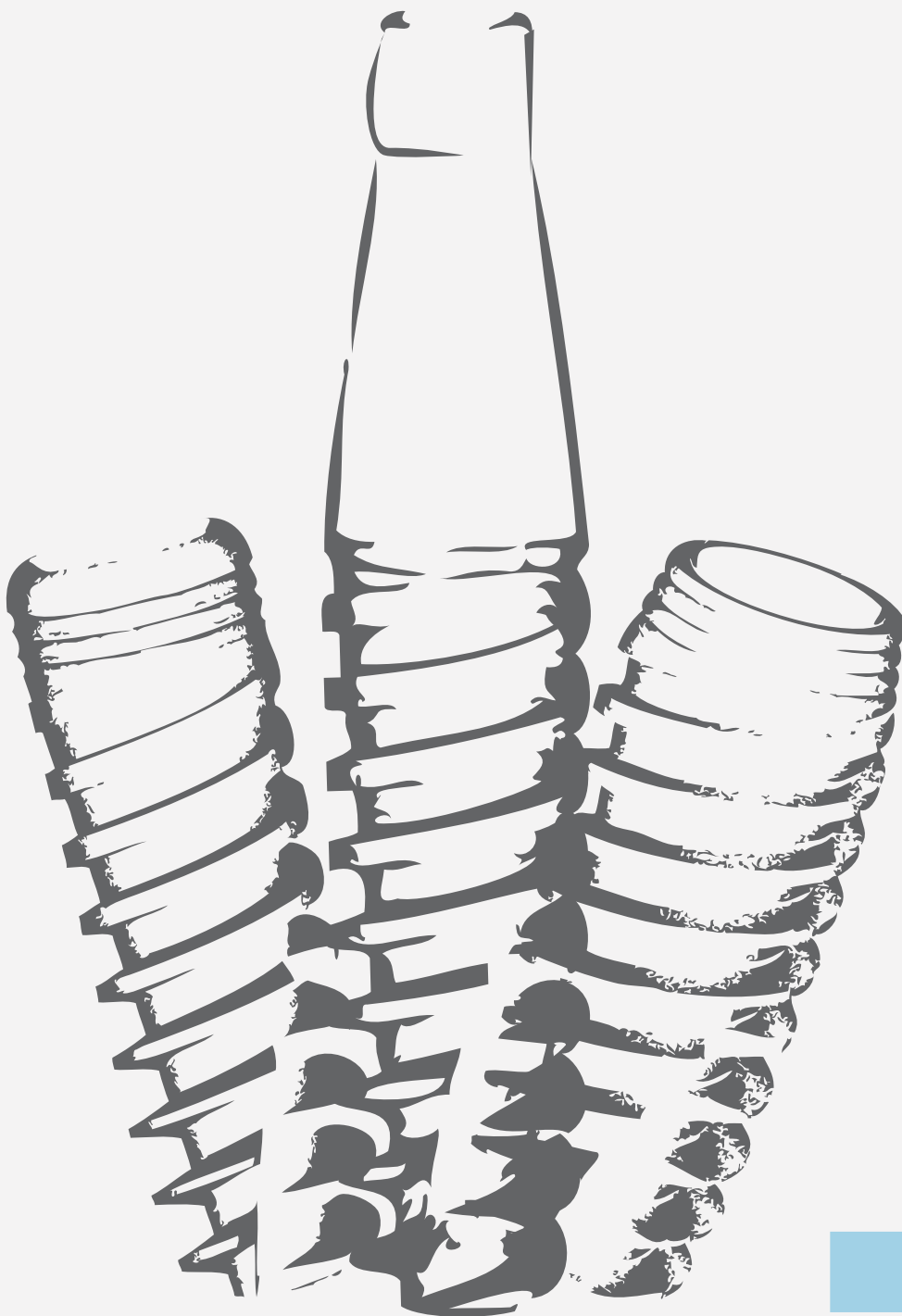


# SCIENTIFIC STUDIES

Selected Abstracts **VOL.1**



**LEAVE  
LIMITS  
BEHIND**

Over the years, Adin has continuously focused on advancing its highly professional research and development team, to ensure the production of technologically advanced high quality products. Adin has also worked closely with the industry's leading dental professionals, surgeons, technicians, in both private and public sectors, along with dental schools in leading Universities, in order to provide customers with the most current, up-to-date industry knowledge and information.

In our strong efforts to assist dental professionals throughout their most complex cases, Adin has composed a collection of professional case study abstracts and scientific studies. These case studies and reports are based on advanced dental research conducted at various Universities and laboratories worldwide, and at regional medical and public health centers.

Adin's commitment to education today will reflect on the future of bettering and improving the world of Implantology. Adin highly values continuous education, offering customers new research opportunities, to explore and review new ideas in the field of Implantology.

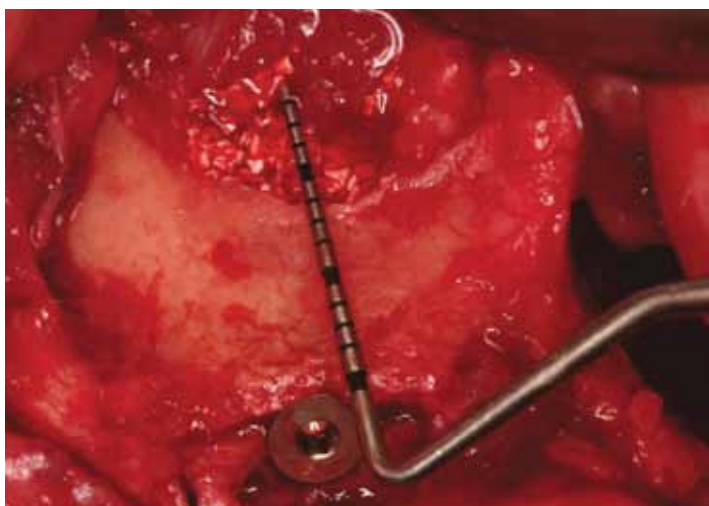
For the complete list of abstracts, please visit our web site at [www.adin-implants.com](http://www.adin-implants.com). For the full text articles, please contact us at +972.4.6426732 or at [info@adin-implants.com](mailto:info@adin-implants.com).

## Nasal Floor Elevation Combined with Dental Implant Placement | Ziv Mazor, DMD; Adi Lorean, DMD; Eitan Mijiritsky, DMD; Liran Levin, DMD

# Case 1

**Objectives:** The aim of the present study was to report on the survival of dental implants placed in conjunction with nasal floor elevation.

**Methods:** A retrospective cohort of 32 consecutive patients from two private practices was evaluated. All patients presented with alveolar bone height deficiency in the anterior region, which was not sufficient to place a dental implant according to a computed tomography (CT) scan performed prior to implantation. Elevation and augmentation of the nasal mucosa was performed simultaneously with dental implant placement. Data collection included demographic information, as well as records of the pre-operative available bone height, implant dimensions, bone addition following nasal floor augmentation, and survival of the implants at last follow-up.



**Results:** Overall, 32 patients received 100 implants that were performed in conjunction with nasal floor elevation. The average pre-operative available bone height according to a CT scan that was performed prior to implantation was  $9.1 \pm 0.9$  mm and ranged from 7.3 to 11.2 mm. Bone addition following nasal floor augmentation was  $3.4 \pm 0.9$  mm and ranged between 1.1 and 5.7 mm. The mean follow-up time was  $27.8 \pm 12.4$  months, and during that follow-up period, no implant failure was recorded, resulting in 100% implant survival.

**Conclusion:** Nasal floor elevation might serve as a predictable procedure, which allows implant placement in areas with significant atrophy together with increased implant stability due to the bicortical support.

Ref.: Mazor Z, Lorean A, Mijiritsky E, Levin L; Nasal Floor Elevation Combined with Dental Implant Placement; Clin. Implant. Dent. Relat. Res., 2010 Oct 26.

# Biomechanical and Histologic Evaluation of Non-Washed Resorbable Blasting Media and Alumina-Blasted/Acid-Etched Surfaces

| Paulo G. Coelho, DDS, PhD; Charles Marin, DDS, MSc; Rodrigo Granato, DDS, MSc; Gabriela Giro, DDS, MSc; Marcelo Suzuki, DDS; Estevam A. Bonfante, DDS, PhD

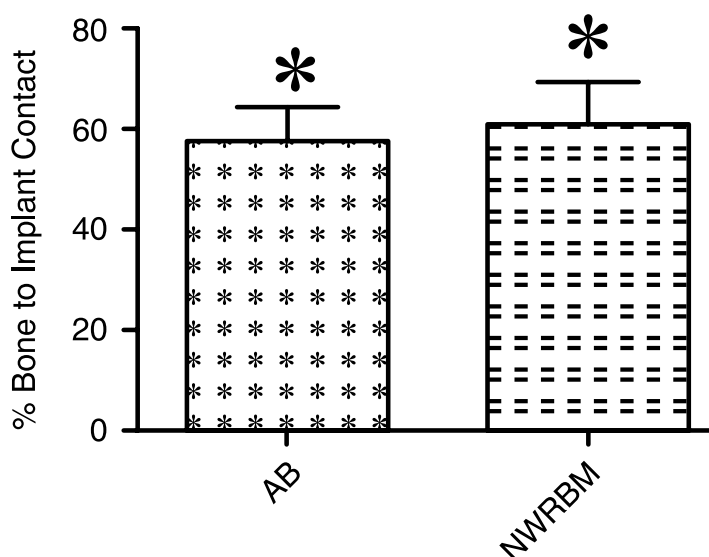
**Objectives:** To compare the biomechanical fixation and histomorphometric parameters between two implant surfaces: non-washed resorbable blasting media (NWRBM) and alumina-blasted/acid-etched (AB/AE), in a dog model.

**Material and methods:** The surface topography was assessed by scanning electron microscopy, optical interferometry and chemistry by X-ray photoelectron spectroscopy (XPS). Six beagle dogs of ~1.5 years of age were utilized and each animal received one implant of each surface per limb (distal radii sites). After a healing period of 3 weeks, the animals were euthanized and half of the implants were biomechanically tested (removal torque) and the other half was referred to nondecalcified histology processing. Histomorphometric analysis considered bone-to-implant contact (BIC) and bone area fraction occupancy (BAFO). Following data normality check with the Kolmogorov-Smirnov test, statistical analysis was performed by paired t-tests at 95% level of significance.

**Results:** Surface roughness parameters Sa (average surface roughness) and Sq (mean root square of the surface) were significantly lower for the NWRBM compared with AB/AE. The XPS spectra revealed the presence of Ca and P in the NWRBM. While no significant differences were observed for both BIC and BAFO parameters ( $P > 0.35$  and  $P > 0.11$ , respectively), a significantly higher level of torque was observed for the NWRBM group ( $P = 0.01$ ). Bone morphology was similar between groups, which presented newly formed woven bone in proximity with the implant surfaces.

**Conclusion:** A significant increase in early biomechanical fixation was observed for implants presenting the NWRBM surface.

Ref.: Coelho PG, Marin C, Granato R, Giro G, Suzuki M, Bonfante EA; Biomechanical and Histologic Evaluation of Non-Washed Resorbable Blasting Media and Alumina-Blasted/Acid-Etched Surfaces; Clin. Oral Impl. Res., 2011 Feb.



LEAVE LIMITS BEHIND

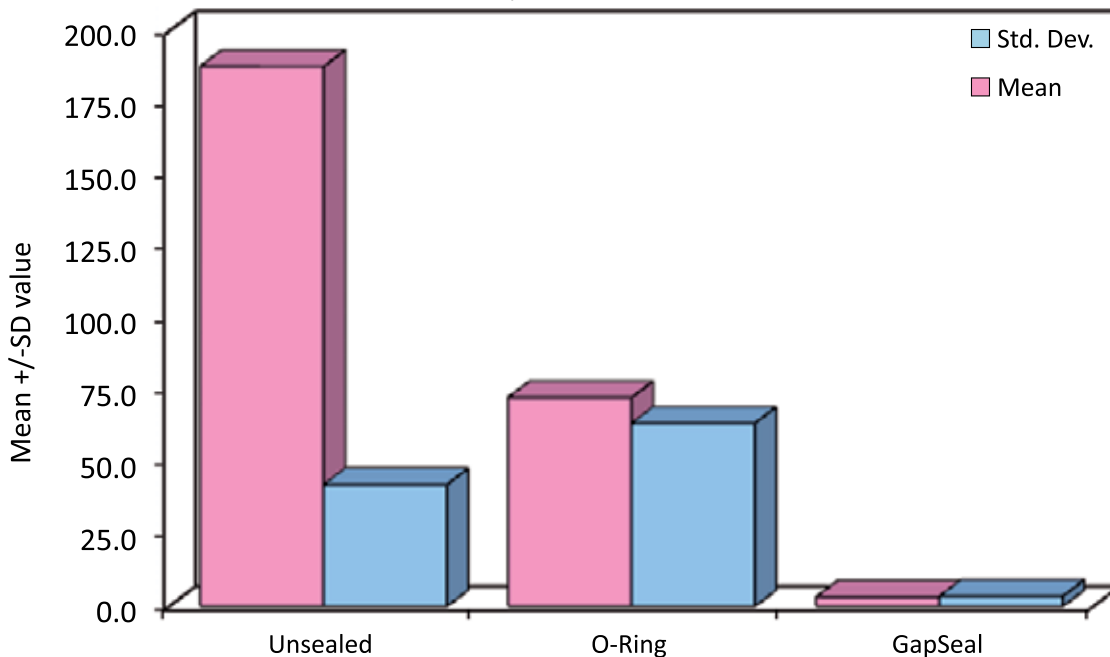
# Efficacy of Antibacterial Sealing Gel and O-Ring to Prevent Micro Leakage at the Implant Abutment Interface – an Invitro Study

| Aishwarya Gajanan Nayak, MDS; Aquaviva Fernandes, MDS; Raghavendra Kulkarni, MDS; Ajantha G.S., MDS; Lekha K., MDS; Ramesh Nadiger, MDS

Gaps and hollow spaces at the implant abutment interface will act as a bacterial reservoir which may cause periimplantitis. Hence, the sealing ability of O-ring [an addition polysiloxane] and GapSeal [an antibacterial sealing gel] was evaluated. A total of 45 identical implant systems of ADIN company were taken and divided into 3 groups with 15 implants in each group. The group labeled U consisted of unsealed implants; the group O consisted of implants sealed with O-rings and the group G implants were sealed with GapSeal gel. The implant and abutment were assembled as per the groups and were gamma sterilized. Two implants from each group were randomly incubated in sterile brain heart infusion broth tubes and checked for sterility. The remaining 13 implants were incubated in BHI broth inoculated with enterococcus and incubated for 5 days. They were then removed from the tubes, dried aseptically, placed in 2% sodium hypochlorite solution for 30 minutes and washed with sterile saline for 5 minutes. Following this the assembly was dried aseptically and put in sterile brain heart infusion broth tubes & incubated for 24 hours in order to check the surface sterility. Keeping 2 implants as control from each group, the remaining 11 implants were dismantled group wise, placed in liquid BHI broth and the test tubes were shaken thoroughly such that the broth comes in contact with all the surfaces of the implants. The solution from this tube was poured on pre-prepared sterile agar plates and incubated for 24 hours; The colonies formed on the agar plate were then counted on a digital colony counter. The data thus obtained was subjected to statistical analysis by Kruskal-Wallis ANOVA test and Mann-Whitney Utest. It was concluded that though microbial growth is seen in all the 3 groups, the least growth was seen in GapSeal group followed by O-ring as compared to the unsealed group.

Ref.: Nayak AG, Fernandes DA, Kulkarni DR, G S DA, K DL, Nadiger DR; Efficacy of Antibacterial Sealing Gel and O-Ring to Prevent Micro Leakage at the Implant Abutment Interface – an Invitro Study; J. Oral Implantol., 2011 May 16

The Effect of Sealing on Implant-Abutment Interface (IAI)



## Clinical and Radiological Evaluation of Two Stage Implant in a Single Stage Procedure and Two Stage Procedure - a Comparative Study |

Rajat Garg, MDS; R.M Borle, MDS, PhD; Abhay N. Datarkar, MDS, PhD

# Case 4

The aim of this study was to estimate and compare the marginal bone loss, pocket formation and stability of two stage implant in single stage procedure and two stage procedure. Sixteen patients with twenty edentulous sites participated in this study. After randomization, 10 edentulous sites received two stage implant with standard protocol of delayed loading and 10 edentulous sites received two stage implant in which immediate abutment is placed. Loading was done for immediate group within 2 days with temporary resin crown. After 3 months, permanent crowns were fabricated for both the groups. A standardized clinical and radiographic evaluation was performed immediately after prosthesis placement and after 6, 12 and 18 months. One implant of the 2-stage group was lost after 3 months. The mean bone loss after 18 months for two stage group was  $1.11 \pm 0.60$  mesially and  $0.88 \pm 0.48$  distally whereas for single stage group was  $1.05 \pm 0.49$  mesially and  $0.70 \pm 0.34$  distally. All implants were stable with no clinical mobility and pocket depth was comparable for the groups. The results of this study suggest that dental implants designed for a submerged implantation procedure inserted in the partially edentulous ridge in a one-stage approach to be at least as predictable as the conventional two-stage technique, suggesting that a two-stage implant system can be safely used for implant insertion in a single stage procedure.

Ref.: Garg R, Borle RM, Datarkar AN; Clinical and Radiological Evaluation of Two Stage Implant in a Single Stage Procedure and Two Stage Procedure – A Comparative Study; Arch. Dent. Res., 2011 Jan-Jun;1:25-30.

## Replacement of a Molar with 2 Narrow Diameter Dental Implants |

Ziv Mazor, DMD; Adi Lorean, DMD; Eitan Mijiritsky, DMD; Liran Levin, DMD

# Case 5

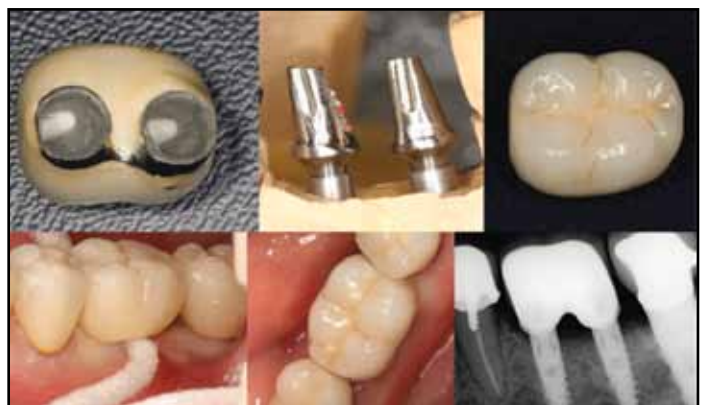**Objectives:** The aim of the present study was to present results of single molar area rehabilitated by 2 narrow diameter dental implants.

**Methods:** A retrospective cohort of 33 consecutive patients from 2 private practices between the years 2009 and 2011 had been evaluated. Patients who had a first molar single replaced by 2 narrow diameter implants (3 mm wide) were included in this case series. Patients' demographics, site and implant characteristics, and time of follow-up were recorded from the medical files.

**Results:** Overall, 33 patients received 66 implants replacing 33 missing first molars. Patients' age ranged from 23 to 76 years with an average of  $49.2 \pm 12.7$  years. Most of the implants were used to replace a mandibular molar (76%) and 16 were used to replace 8 maxillary molars. In 2 patients, immediate implantation was performed. The mean distance between the adjacent teeth was  $12.1 \pm 1.0$  mm. Follow-up time ranged from 10 to 18 months (average,  $12.2 \pm 1.9$  months). All implants survived the follow-up time. One implant presented with 1 mm of bone loss at 12-month follow-up.

**Conclusion:** Replacing a single missing molar with 2 narrow diameter dental implants might serve as a viable treatment option providing good and predictable long-term results.

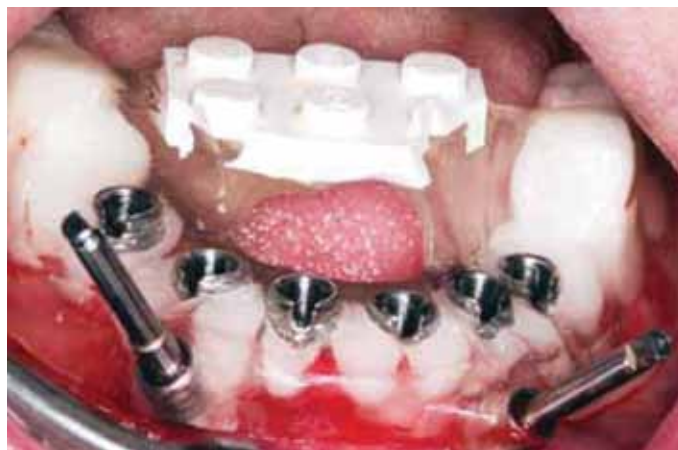Ref.: Mazor Z, Lorean A, Mijiritsky E, Levin L; Replacement of a Molar with 2 Narrow Diameter Dental Implants; Implant Dent., 2011 Sep 16.



## Full-Mouth Implant-Supported Rehabilitation with a Flapless Surgical Technique: a Treatment Approach Using Computer-Assisted Oral Implant Surgery | Eitan Mijiritsky, DMD; Adi Lorean, DMD; Horia Barbu, DMD, PhD; Ziv Mazor, DMD

Successful implant treatment includes osseointegration as well as prosthetically optimal positions of the implants for esthetics and function. Computer-assisted oral implant surgery offers several advantages over the traditional approach. The purpose of this report was to evaluate a complex case of a 28-year-old female patient who lost all her teeth as a result of an aggressive periodontal disease resulting in severe vertical and horizontal bone loss. The patient underwent a bilateral open sinus lift procedure and after 6 months dental implants were placed in both jaws with the help of computerized tomography (CT)-based software planning and computer-assisted manufacture of a laboratory-based acrylic surgical guide.

A total of 13 dental implants were placed in both jaws using a flapless approach followed by immediate loading of the implants and implant-supported full arch fixed dentures.



Ref.: Mijiritsky E, Lorean A, Barbu H, Mazor Z; Case Report: Full-Mouth Implant-Supported Rehabilitation with a Flapless Surgical Technique: A Treatment Approach using Computer-Assisted Oral Implant Surgery; Int. J. Oral Impl. Clin. Res., 2011 Sep-Dec;2(3):171-175.

## Effect of Implant Diameter on Reliability and Failure Modes of Molar Crowns | Amilcar C. Freitas-Junior, DDS, PhD; Estevam A. Bonfante, DDS, PhD; Leandro M. Martins, DDS, MSc; Nelson R.F.A Silva, DDS, PhD; Leonard Marotta, DDS, PhD; Paulo G. Coelho, DDS, PhD



The reliability and failure modes of molar crowns supported by three different implant-supported designs were tested according to the following groups: group 1, one standard diameter implant (3.75 mm); group 2, one narrow-diameter implant (3 mm); and group 3, two narrow-diameter implants (3 mm). Loads were applied as mouth-motion cycles using a step-stress accelerated life-testing method.  $\beta$  values for groups 1 and 3 (1.57 and 2.48, respectively) indicated that fatigue accelerated the failure of both groups, but not for group 2 (0.39). Abutment screw failure was the chief failure mode. Strength and reliability were significantly higher for groups 1 and 3 compared to group 2.

Ref.: Freitas-Junior AC, Bonfante EA, Martins LM, Silva NR, Marotta L, Coelho PG; Effect of Implant Diameter on Reliability and Failure Modes of Molar Crowns; Int. J. Prosthodont., 2011 Nov-Dec;24(6):557-61.

## Flapless Approach to Maxillary Sinus Augmentation Using Minimally Invasive Antral Membrane Balloon Elevation |

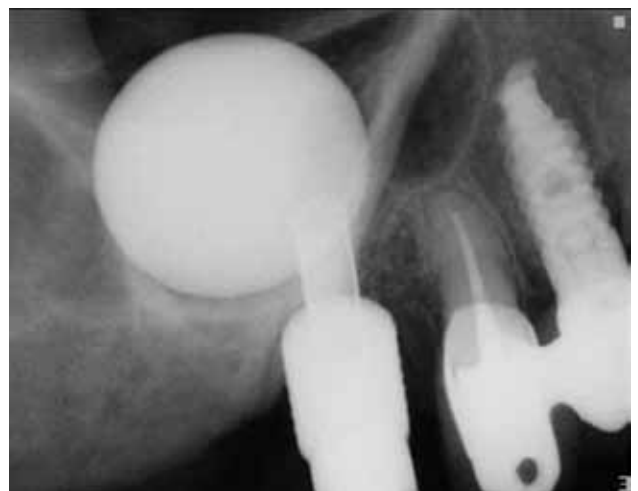Ziv Mazor, DMD; Efraim Kfir, DMD; Adi Lorean, DMD; Eitan Mijiritsky, DMD; Robert A. Horowitz, DDS

# Case 8

LEAVE LIMITS BEHIND

In the atrophic posterior maxilla, successful implant placement is often complicated by the lack of quality and volume of available bone. In these cases, sinus floor augmentation is recommended to gain sufficient bone around the implants. Sinus elevation can be performed by either an open lateral window approach or by a closed osteotome approach depending on available bone height. This case series demonstrates the feasibility and safety of minimally invasive antral membrane balloon elevation, followed by bone augmentation and implant fixation in 20 patients with a residual bone height of 2 to 6 mm below the sinus floor. The surgical procedure was performed using a flapless approach. At 18 months follow-up, the implant survival rate was 100%. Absence of patient morbidity and satisfactory bone augmentation with this minimally invasive procedure suggests that minimally invasive antral membrane balloon elevation should be considered as an alternative to some of the currently used methods of maxillary bone augmentation.

Ref.: Mazor Z, Kfir E, Lorean A, Mijiritsky E, Horowitz RA; Flapless Approach to Maxillary Sinus Augmentation Using Minimally Invasive Antral Membrane Balloon Elevation; *Implant Dent.*, 2011 Dec;20(6):434-8.





Adin Dental Implant Systems LTD  
Industrial Zone Alon Tavor  
POB 1128, Afula 1811101, Israel  
Tel: +972-4-6426-732  
Fax: +972-4-6426-733